



Since January 2020 Elsevier has created a COVID-19 resource centre with free information in English and Mandarin on the novel coronavirus COVID-19. The COVID-19 resource centre is hosted on Elsevier Connect, the company's public news and information website.

Elsevier hereby grants permission to make all its COVID-19-related research that is available on the COVID-19 resource centre - including this research content - immediately available in PubMed Central and other publicly funded repositories, such as the WHO COVID database with rights for unrestricted research re-use and analyses in any form or by any means with acknowledgement of the original source. These permissions are granted for free by Elsevier for as long as the COVID-19 resource centre remains active.

- [7] Peiris JS, Yu WC, Leung CW, et al. Re-emergence of fatal human influenza A subtype H5N1 disease. *Lancet*. 2004;363:617–619.
- [8] Peramivir ([www.biocryst.com/pdf/peramivirfacts.pdf](http://www.biocryst.com/pdf/peramivirfacts.pdf)).
- [9] Tiensin T, Chaitaweesub P, Songserm T, et al. A highly pathogenic avian influenza H5N1, Thailand 2004. *Emerg Infect Dis*. 2005;11:1664–1672.
- [10] deJong MD, Bach VC, Phan TQ, et al. Fatal avian influenza A H5N1 in a child presenting with diarrhea followed by coma. *N Engl J Med*. 2005;352:686–691.
- [11] Chotpitayasunondh T, Ungchusak K, Hanshaoworakul W, et al. Human disease from influenza A (H5N1), Thailand 2005. *Emerg Infect Dis*. 2005;11:201–209.
- [12] Yuen KY, Wong SSY. Human infection by avian influenza A H5N1. *Hong Kong Med J*. 2005;11:189–199.
- [13] McFee RB. Avian Influenza: The Next Pandemic? *Disease a Month*. 2007;53(7)348–358.
- [14] US Food and Drug Administration (FDA) Flu information (<http://www.fda.gov/oc/opacom/hottopics/flu.html>).
- [15] Sun Y, Liu J. H9N2 influenza virus in China: a cause of concern. *Protein Cell*. 2015;6(1)18–25.
- [16] Kimble JB, Angel M, Wan H, Sutton TC, et al. Alternative reassortment events leading to transmissible H9N1 influenza viruses in the ferret model. *J Virol*. 2014;88:66–71.
- [17] Sun Y, Qin K, Want J, Pu J, Tang Q, et al. High genetic compatibility and increased pathogenicity of reassortants derived from avian H9N2 and pandemic H1N1 2009 influenza viruses. *Proc Natl Acad Sci USA*. 2011;108:4164–4169.
- [18] Sorrell EM, Wan H, Araya Y, Song H, Perez DR. Minimal molecular constraints for respiratory droplet transmission of an avian-human H9N2 Influenza A virus. *Proc Natl Acad Sci USA*. 2009;106:7565–7570.
- [19] Cong YL, Pu J, Liu QF, Wang S, et al. Antigenic and genetic characterization of H9N2 swine influenza viruses in China. *J Gen Virol*. 2007;88:2035–2041.
- [20] Sun Y, Pu J, Fan L, Sun H, et al. Evaluation of the protective efficacy of a commercial vaccine against different antigenic groups of H9N2 influenza virus in chickens. *Vet Microbiol*. 2012;156:193–199.
- [21] Li C, Yu K, Tian G, Yu D, et al. Evolution of H9N2 influenza viruses from domestic poultry in Mainland China. *Virology*. 2005;340:70–83.
- [22] World Health Organization Influenza at the Human animal interface Summary 16 Jan 2017 ([www.who.int/wer/en](http://www.who.int/wer/en)).
- [23] Shaghavagh R, Alizadeh A, Alizadeh E, Hossein SM. The avian influenza H9N2 at avian human interface: a possible risk for future pandemics. *J Res Med Sci*. 2016;21:51 Available at (<https://www.ncbi.nlm.nih.gov/pmc/articles/PMC5216463/?report=printable>).
- [24] Monto AS, Gravenstein S, Elliott M, Colopy M, Schweinle J. Clinical signs and symptoms predicting influenza infection. *Arch Intern Med*. 2000;160:3243–3247.
- [25] Tran TH, Nguyen TL, Nguyen TD, et al. WHO Avian Influenza Investigative team. Avian influenza A H5N1 in 10 patients in Vietnam. *N Engl J Med*. 2004;363:617–619.
- [26] Tuabemberger JK, Reid AH, Lourens RM, et al. Characterization of the 1918 influenza virus polymerase genes. *Nature*. 2005;4437:889–893.
- [27] Taisuke H, Kawaaka Y. Influenza: lessons from past pandemics, warnings from current incidents. *Nat Rev Microbiol*. 2005;5:591–600.
- [28] WHO Avian influenza and the significance of transmission to humans ([http://www.who.int/mediacentre/factsheets/avian\\_influenza/en](http://www.who.int/mediacentre/factsheets/avian_influenza/en)).
- [29] Sidwell RW, Smee DF. Peramivir, potential new therapy for influenza. *Expert Opin Invest Drug*. 2002;11:859–869.
- [30] Peramivir (<http://www.cidrap.umn.edu/news-perspective/2014/12/fda-approval-peramivir-makes-iv-flu-drug-available>) Last accessed 02/13/17.
- [31] (<https://www.fda.gov/NewsEvents/Newsroom/PressAnnouncements/ucm427755.htm>).
- [32] (<http://www.virology.ws/2009/04/30/structure-of-influenza-virus/>).

## EMERGING PATHOGENS: INFLUENZA - H7N9

In March 2013 human infections from a newly noted avian influenza A virus (H7N9) (Figure 3 (1)) first were reported from China [2,3], with ongoing epidemics occurring annually. As with other influenza viruses there is a seasonal variation, where highest levels are noted in cold weather months. As reported to WHO [1], as of 2017 this is the fifth epidemic of H7N9 human infection. By 01/16/17 there were 918 cumulative reported cases, associated with 359 deaths. Most cases are associated with exposure to poultry [1–8], which is not an uncommon risk factor for avian influenza infection, as has been seen in prior epidemics involving H5N1 [9], and others (Figure 4) [10].

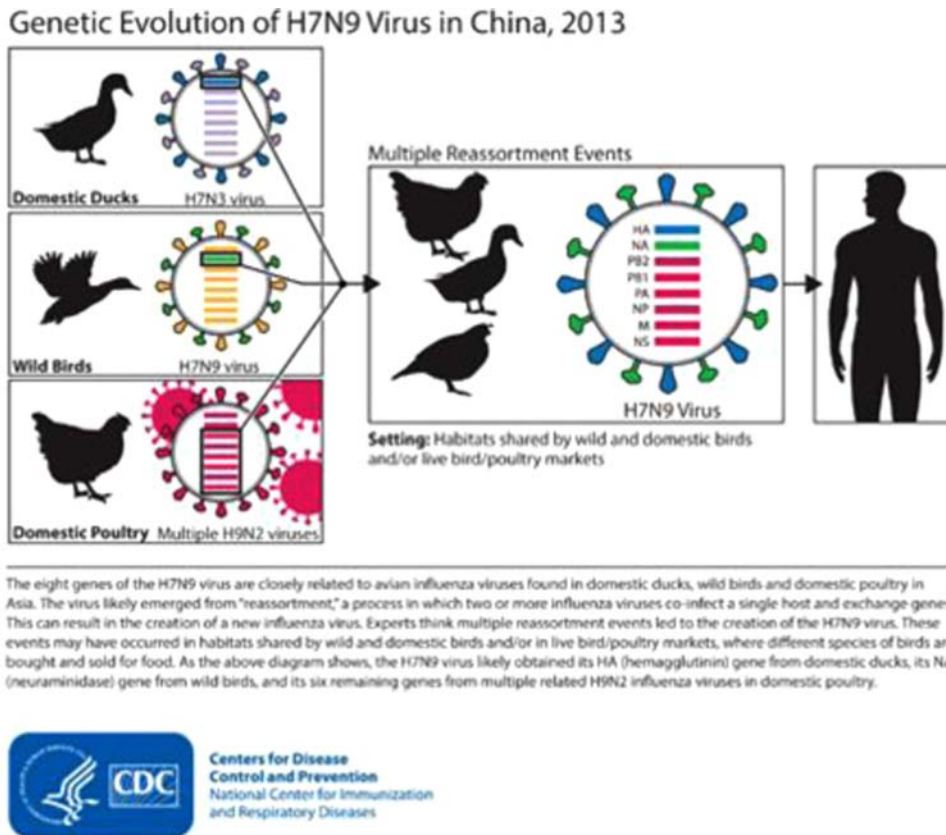
Unlike more seasonal and low pathogenicity influenza virus infections, H7N9 associated infection results in severe respiratory illness [2–8,10–18], not unlike H5N1.

According to updated CDC information [3], China is currently experiencing its 5th epidemic of H7N9 human infections. On February 20, 2017, the World Health Organization (WHO) updated information on H7N9. WHO announced that 424 human infections with H7N9 virus have been reported during this 5th epidemic. This is the largest one to date. And it brings the total cumulative number of H7N9 cases reported by WHO to 1,223. Of note, approximately 40 percent of people confirmed with H7N9 infection have died according to WHO data.

Fig. 3 - Influenza virus H7N9 CDC Electron micrograph [1].

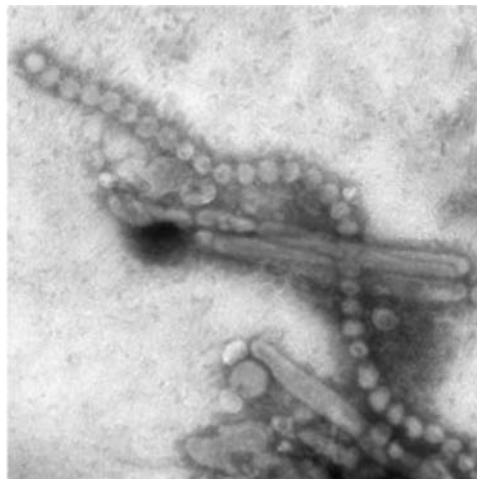

Fig. 4 Animal – Human Interface H7N9 CDC [2]



Human avian influenza A (H7N9) is a novel reassortant virus that was isolated from throat-swab specimens collected from three early infected patients [5,8]. Infections with H7N9 influenza virus usually results from exposure to birds or wild poultry [4–6,8]. Illness will commonly present with acute onset, rapid progression, poor prognosis, and high mortality rate [5,8].

### Clinical Presentation

From the Ma et al study, fever and cough with sputum production are the initial clinical manifestations [8]. The condition of the H7N9-infected patients deteriorates rapidly with acute respiratory distress syndrome (ARDS), multisystem organ failure and death [4,5,8]. According to the CDC most reported patients with H7N9 virus infection have had severe respiratory illness (e.g., pneumonia), with approximately 40% of patients having died [3].

Early diagnosis and rapid initiation of antiviral treatment are essential to reducing the morbidity and potential mortality associated with H7N9. Other reports reveal signs and symptoms that vary from relatively mild flu like symptoms, to high fever, and rapidly progressive pneumonia unresponsive to antibiotic antimicrobials [8,11–16]. As such, deterioration to severe hypoxemia, tachypnea and respiratory failure can occur. Extrapulmonary findings include altered consciousness, renal impairment, and heart failure. Less severe findings include conjunctivitis [4, 5, 8, and 11].

Based upon the study by Ma et al. to evaluate radiographic studies associated with laboratory confirmed H7N9, the following cascade of symptoms were noted (Table 1) [8]. These are consistent with WHO and CDC information.

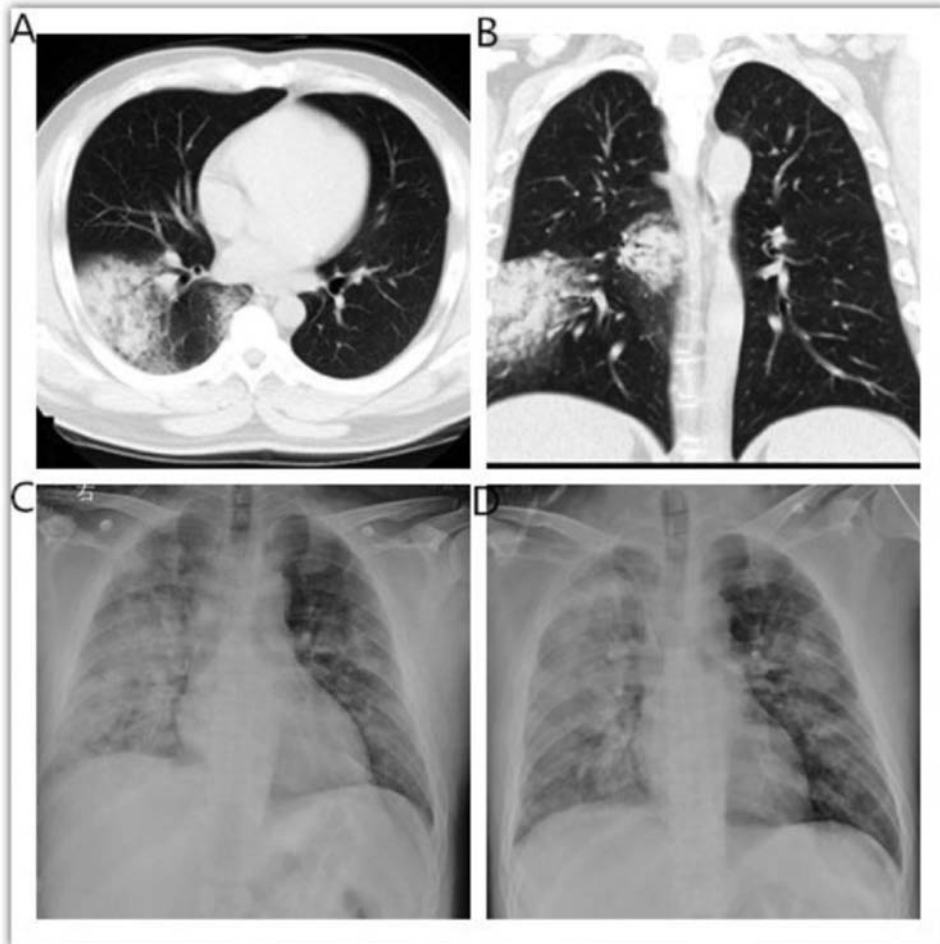
### Radiological Testing

Chest XRay (CXR) and chest computed tomography (CT) are the mainstay of initial radiographic investigation, especially with rapidly progressive respiratory symptoms [8,11–15]. This is especially true with the imaging of pulmonary inflammation [11–16]. Taken together, CXR and/or CT findings, with clinical manifestations and laboratory results provide clues for the diagnosis of the HPAI infections, or other pulmonary processes that can cause the picture of ARDS [17]. Of note, Ma et al [8] utilized the radiologic findings of patients with avian influenza H7N9 pneumonia to characterize severe disease; the diagnosis was confirmed with oropharyngeal specimens found positive for H7N9.

The Ma et al results revealed abnormal findings on chest radiological images from all patients [8]. The initial radiological findings of 5 patients with H7N9 virus infection began with just unilateral one-lobe involvement, the right lower lobe in case 2 and case 4. The most common findings were ground glass opacities (GGOs) in all the five patients, and area/s of consolidation with air bronchogram and ipsilateral pleural effusion in four patients (Figure 5) [8]. Most cases revealed a mixed pattern of GGO and consolidation, which is consistent with previous reports [8,11–19].

In Wang QL et al (Figure 6) [11] they reported 12 patients with H7N9 virus infection and radiological findings included GGOs (in 12 of 12 patients), consolidations (in 11 patients), and air bronchograms (in 11 patients). Not surprisingly, viral pneumonias with consolidation carry a worse prognosis. The findings of ARDS do not differ significantly from SARS [17].

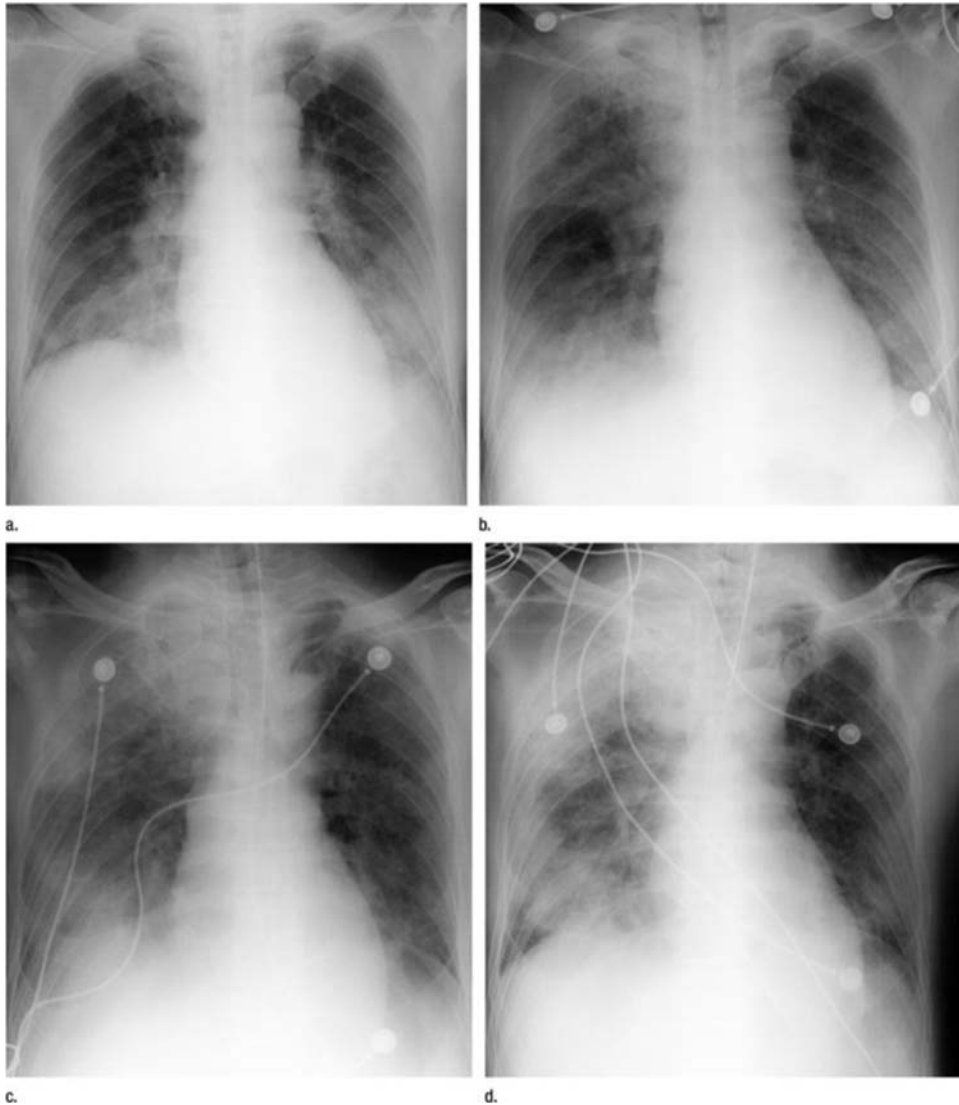
Fig. 5 CT sectional and coronal views show the multi-segment lesions of GGOs and consolidations in the right lower lobe. C and D: Bedside chest X-ray four days later (C) demonstrated bilateral pulmonary involvement and developed rapidly on the 5th day (D). Right pleural effusion is also shown [8].



Lin et al conducted a study to characterize the XRay and Computed Tomography (CT) findings associated with early human H7N9 infection [20]. Studies were obtained within 1 – 20 days of onset.

Although a small study [20], the findings are worth noting, and consistent with the Wang et al study of H7N9 infections [11], as well as severe pulmonary findings associated with Middle East Respiratory Syndrome (MERS) [21], and other aggressive pulmonary infections [17,22,23]. In the Lin et al study all of the cases had acute onset [20]. Their findings revealed abnormal X-ray and CT findings in all patients. In the early stage, the right lung was more commonly affected (particularly in the right upper and middle lobes). The lesions rapidly expanded to include the entire lungs and were characterized primarily by ground-glass opacities (GGOs) combined with consolidation. Diffuse GGO was observed in all six cases (1 was symmetric, and 5 were non-symmetric). Local consolidation was found in four cases, and lobar consolidation was found in two cases. Normal lung tissue was observed between the lesions. Pleural thickening was common and was combined with pleural/pericardial effusion or mediastinal lymph node enlargement. Reticular changes, centrilobular nodules, and the tree-in-bud sign were observed in some cases, but reticular changes, bronchial wall thickening, and hyperinflation were not found.

Fig. 6 (a–d) Anteroposterior chest radiographs obtained with portable bedside unit in 56-year-old man with H7N9 influenza on (a) day 7, (b) day 8, (c) day 9, and (d) day 10 after onset of illness. The series of radiographs shows rapid daily progression of areas of increased opacity and consolidation. A clear interlobar fissure margin is seen on day 8 (in b). (c) At 9 days after onset (3 days after admission), the patient's condition deteriorated, with shortness of breath, chest distress, and blood oxygen saturation of 80%–85%, and the patient was intubated with an invasive ventilator [11].



In addition to a thorough clinical history, comprehensive examination, and radiographic studies, blood tests, with focus on systemic involvement, should be considered.

### LABORATORY CONFIRMATION

Leukopenia, lymphopenia, thrombocytopenia, impaired renal function tests, and an increase in myocardial enzymes, as well as increased aspartate aminotransferase have been noted. With progression of illness, increased serum cytokines, chemokines and markers for disseminated intravascular coagulation (DIC), have been observed. [18–20].

Molecule confirmation using reverse transcription polymerase chain reaction (rt PCR) assay is required. Rapid influenza testing at the point of care will not type the influenza if present, but can give an indicator as to illness.

In April 2014 the FDA gave emergency and limited approval for Arbor Vita's rapid H7N9 test. Other rapid tests are in various stages of development.

As of the updated H7N9 laboratory section [24], the CDC has developed the diagnostic test materials to specifically detect the new avian influenza A (H7N9) virus found in China. These include rRT-PCR reagents (primers and probes), controls

and an rRT-PCR test protocol. U.S. qualified public health laboratories only can order the CDC H7N9 reagents and the positive control. The CDC H7N9 RT-PCR reagents and controls are intended for use in conjunction with CDC's existing test kit (the Flu rRT-PCR Dx Panel) that is currently used by U.S. public health laboratories. Non public health entities can obtain primer sequences or testing protocols from the CLSIS website. The CDC provides a variety of references and points of contact:

CDC's H7N9 rRT-PCR test protocol is available via CDC's Laboratory Support of Influenza Surveillance (CLSIS) Sharepoint website (<https://www.cdc.gov/flu/clsis/index.htm>). The CLSIS Sharepoint site provides technical support and guidance for influenza surveillance testing. As a registered user, laboratories will have access to influenza testing protocols as well as other technical support resources. All future updates and communications will be provided via this SharePoint site. For further information or assistance, an email can be sent to [clsis@cdc.gov](mailto:clsis@cdc.gov).

The reader is referred to the CDC [24] for current updates on clinical and laboratory guidance. <https://www.cdc.gov/flu/avianflu/h7n9/detecting-diagnostics.htm>

## TREATMENT

According to the CDC [25], standard dosing of Oseltamivir remains the current treatment of choice for general influenza infection, and H7N9. The treatment dose is 75 mg twice daily for 5 days, ideally within 2 days of symptom onset [19,20]. Beyond that window, some benefit may be realized; risk benefit must be taken into consideration. The prophylaxis dosing 75 mg once daily for at least 10 days, within 10 days of exposure. Other neuraminidase inhibitors can be considered based upon risk benefit and clinical status of the patient.

## VACCINES

CDC has developed three H7N9 candidate vaccine viruses (CVV), which are antigenically like circulating viruses during the 4<sup>th</sup> epidemic [25]. The CDC is conducting genetic and antigenic analysis of viruses from the 5<sup>th</sup> epidemic to determine if an additional CVV is needed, as well as determine if 5<sup>th</sup> epidemic viruses are susceptible to current antiviral therapies (neuraminidase inhibitors). At present H7N9 has not acquired the ability for efficient person to person spread.

## PREVENTION

It is important to engage in dialogue with patients about upcoming travel plans, especially to regions known to have H7N9 illness, and to provide information about protective strategies. Basic to all good preventive strategies is having up to date vaccines. These include influenza, and possibly others such as diphtheria, tetanus, pertussis booster, pneumonia, and other immunizations referable to current health threats to region/s to be visited. Referral to travel clinic is useful. Patients should be aware that it can take upwards of several weeks before the body responds to the vaccine in terms of protective response.

In terms of H7N9, and other emerging pathogens, as will be discussed in the next section, increasing patient awareness of animal to human health risks is critical.

Avoiding poultry markets and farms in regions known to have endemic avian influenza viruses – largely Eurasia, along with eating fully cooked eggs and poultry, frequent hand washing, as well as washing clothes upon return to hotel after being in situations where human-animal interaction in endemic regions, are important, basic risk reduction strategies, along with obtaining yearly flu vaccination.

Reminding patients who return with a respiratory illness to provide detailed information about potential areas of exposure to the treating clinician, alerting providers about regions visited, may hasten diagnosis.

Table 1 [8] Summary of clinical information for patients with H7N9 avian influenza.

Case	1	2	3	4	5
Gender	Male	Male	Male	Male	Male
Age	29	33	59	35	51
Time to hospital admit (days after onset)	4	4	7	4	
Poultry exposure	Yes	Unknown	Unknown	Unknown	Unknown
Smoker	Yes	Yes	Yes	Yes	Yes
Comorbidities	Diabetes (DM)	No	HTN/Gout/DM	No	DM
Temp (C)	39	39.5	39.5	39.5	38.5
Cough	Yes	Yes	Yes	Yes	Yes
Sputum	Yes	Yes	Yes	Yes	Yes
WBC	Normal	Normal	Normal	Normal	Normal
Lymphocytes	Decreased	Decreased	Decreased	Decreased	Decreased
LDH	Increased	Increased	Increased	Increased	Increased
CRP	Increased	Increased	Increased	Increased	Increased
CK	Increased	Increased	Increased	Increased	Increased

## REFERENCES

- [1] H7N9 CDC Electron micrograph (<https://www.cdc.gov/flu/avianflu/h7n9-images.htm>).
- [2] World Health Organization H7N9 ([http://www.who.int/influenza/human\\_animal\\_interface/influenza\\_summary\\_in\\_HA\\_interface\\_01\\_16\\_2017\\_Final.pdf](http://www.who.int/influenza/human_animal_interface/influenza_summary_in_HA_interface_01_16_2017_Final.pdf)).
- [3] Avian Influenza A (H7N9) Virus. Centers for Disease Control and Prevention (<https://www.cdc.gov/flu/avianflu/h7n9-virus.htm>).
- [4] Chen Y, Liang WF, Yang SG, Wu NP, Gao HN, Sheng JF, et al. Human infections with the emerging avian influenza A H7N9 virus from wet market poultry: clinical analysis and characterization of viral genome. *Lancet*. 2013;381(9881)1916e25.
- [5] Gao RB, Cao B, Hu YW, Feng ZJ, Wang DY, Hu WF, et al. Human infection with a novel avian-origin influenza A(H7N9) virus. *N Engl J Med*. 2013;368(20)1888e97.
- [6] Uyeki TM, Cox NJ. Global concerns regarding novel influenza A (H7N9) virus infections. *N Engl J Med*. 2013;368(20)1862e4.
- [7] Shi JD, Xie J, He ZB, Hu YW, He YC, Huang QH, et al. A detailed epidemiological and clinical description of 6 human cases of avian-origin influenza A (H7N9) virus infection in Shanghai. *PLoS One*. 2013;8(10)e77651.
- [8] Ma H, Zhu Z, Zin Y, Shen Y, et al. Radiological findings of chest in patients with H7N9 avian influenza from a hospital. *Radiology of Infectious Diseases*. 2015;2(4)177–182. <http://dx.doi.org/10.1016/j.jrid.2015.11.010> Last accessed 02/13/17.
- [9] McFee RB, Bush LM, Boehm KM. Avian influenza: critical considerations for primary care physician. *Johns Hopkins Adv. Stud Med*. 2006;6(10)431–40.
- [10] Animal – Human Interface H7N9 CDC (<https://www.cdc.gov/flu/avianflu/h7n9-images.htm>).
- [11] Wang QL, Zhang ZY, Shi YX, Jiang YB. Emerging H7N9 influenza A (novel reassortant avian-origin) pneumonia: radiologic findings. *Radiology*. 2013;268(3)882e9.
- [12] Feng F, Xia GL, Wang QL, Shi YX, Zhang ZY. Initial computed tomography findings of pneumonia in patients with human infected avian influenza (H7N9). *Radiol Infect Dis*. 2015;1:57e63.
- [13] Lin ZQ, Xu XQ, Zhang KB, Zhuang ZG, Liu XS, Zhao LQ, et al. Chest X-ray and CT findings of early H7N9 avian influenza cases. *Acta Radiol*. 2015;56(5)552e6.
- [14] Li L, Li HJ, Zhao J, Ren MJ. Thoracic imaging features of 13 patients with H7N9 subtype avian influenza virus infection. *Radiol Pract*. 2014;29(7)748e50.
- [15] Dai J, Zhou XM, Dong DJ, Liu Y, Gu Q, Zhu B, et al. Human infection with a novel avian-origin influenza A (H7N9) virus: serial chest radiographic and CT findings. *Chin Med J*. 2014;127(12)2206e11.
- [16] Lu SH, Xi XH, Zheng YF, Cao Y, Liu XN, Lu HZ. Analysis of the clinical characteristics and treatment of two patients with avian influenza virus (H7N9). *Biosci Trends*. 2013;7(2)109e12.
- [17] Grinblat L, Shulman H, Glickman A, Matukas L, Paul N. Severe acute respiratory syndrome: radiographic review of 40 probable cases in Toronto, Canada. *Radiology*. 2003;228(3)802e9.
- [18] Wiwanitkit V. H7N9 Influenza: The emerging Infectious Disease. *N Am J Med Sci*. 2013;5(7)395–398.
- [19] Centers for Disease Control and Prevention (CDC). Emergence of avian influenza A (H7N9) Virus causing severe human illness China. February April 2013. *MMWR Morb Mortal Wkly Rep*. 2013;62:366–371.
- [20] Lin ZQ, Xu XQ, Zhang KB, Zhuang ZG, et al. Chest XRay and Computed Tomography (CT) Findings of early H7N9 Avian Influenza cases. *Acta Radiologica*. 2015;56(5)552–556.
- [21] Aylan AM, Ahyad RA, Jamjoom LG, Alharthy A, Madani TA. Middle East Respiratory Syndrome Coronavirus (MERS – CoV\_ Infection: Chest CT Findings. *AJR*. 2014;203:782–787.
- [22] Gill JR, Sheng ZM, Ely SF, et al. Pulmonary pathologic findings of fatal 2009 pandemic influenza A/H1N1 viral infections. *Arch Pathol. Lab Med*. 2010;134:235–243.
- [23] Marchiori E, Zanetti G, Fontes C, Santos M. Influenza A (H1N1) virus associated pneumonia: high resolution computed tomography – pathologic correlation. *Eur J Radiol*. 2011;80:e500–e504.
- [24] CDC Guidance on testing for H7N9 (<https://www.cdc.gov/flu/avianflu/h7n9/detecting-diagnostics.htm>).
- [25] Interim Guidance on the use of antiviral agents for treatment of human infections with Avian Influenza A H7N9 ([http://www.cdc.gov/flu/avianflu/h7n9\\_antiviral-treatment.htm](http://www.cdc.gov/flu/avianflu/h7n9_antiviral-treatment.htm)).

## EMERGING RESPIRATORY DISEASE - CORONAVIRUSES

### CORONAVIRUSES – AN OVERVIEW

Coronaviruses (CoV) are a diverse group of viruses capable of infecting humans, and a wide range of animals. CoV affect multiple systems, and can cause respiratory, gastrointestinal, hepatic, and neurological illnesses, ranging from mild sickness to death. CoV are classified into multiple genera, including Alpha, Beta, Gamma and Delta coronaviruses. [1–10]. Of note, CoV seem to be able to adapt to new hosts and changing environments; this may be related to CoV ability to mutate and recombine [1,3,5,7], perhaps contributing to novel viruses with varying human pathogenicity.

Coronaviruses (order Nidovirales, family *Coronaviridae*, genus *Coronavirus*) are large, enveloped, single stranded, positive-sense RNA viruses, capable of infecting a variety of animals, including bats, mice, birds, dogs, pigs, cattle, and humans.

Identified many decades ago, Coronavirus (Figure 7 [9] – from the Latin *corona* (translation “crown” or “halo”) represents the appearance of CoV virions as they are viewed through an electron microscope [2,7–10]. The virus appearance is created by viral spikes (S), peplomers that populate the surface and determine host tropism (Figure 7) [8–10].

Fig. 7 Coronavirus. Centers for Disease Control and Prevention (CDC)/Dr. Fred Murphy [9].

